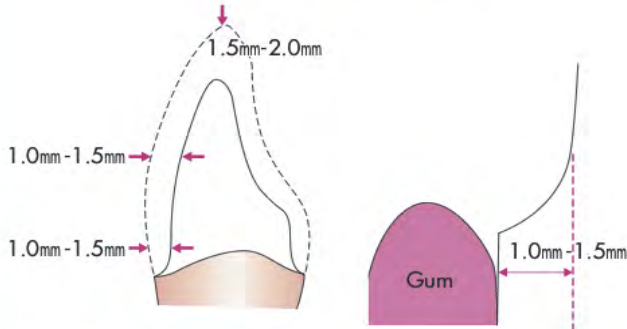
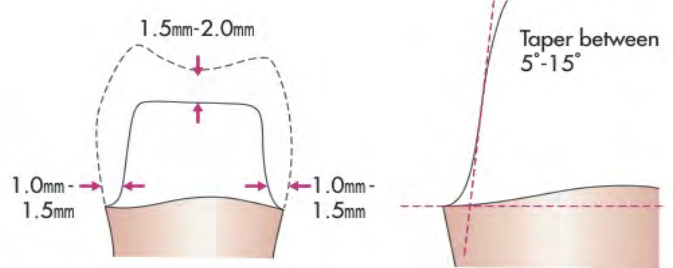


IDEAL DIE PREPARATION

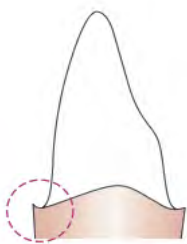
Anterior Crowns



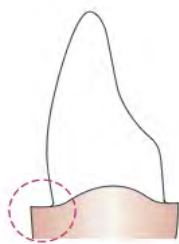
Posterior Crowns



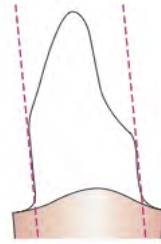
CONTRAINdicATIONS



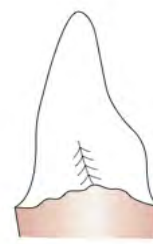"J" Margin



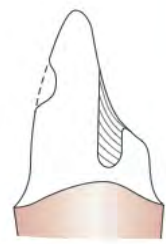
Deep Shoulder



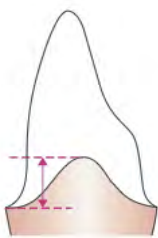
Parallel Axis



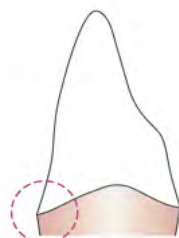
Rough Margin



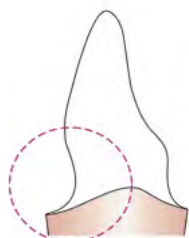
Grooves



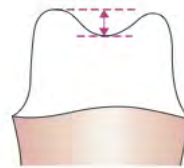
Different Height (Anterior)



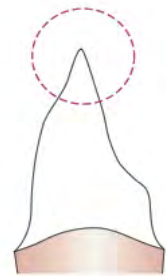
Knife Edge



Undercuts



Different Height (Posterior)



Sharp Incisal Top